

CASE STUDY

Medial closing distal femur osteotomy in a young patient with isolated lateral compartment knee osteoarthritis



PHYSICIAN PROFILE :

Prof. Dr. Seil Romain, MD, PhD

Department of Orthopaedic Surgery, Centre Hospitalier de Luxembourg –
Clinique d'Eich (Luxembourg)



Active member of : ESSKA, ISAKOS, GOTS, AGA, SFA, LIROMS,
ACL study group

PATIENT HISTORY

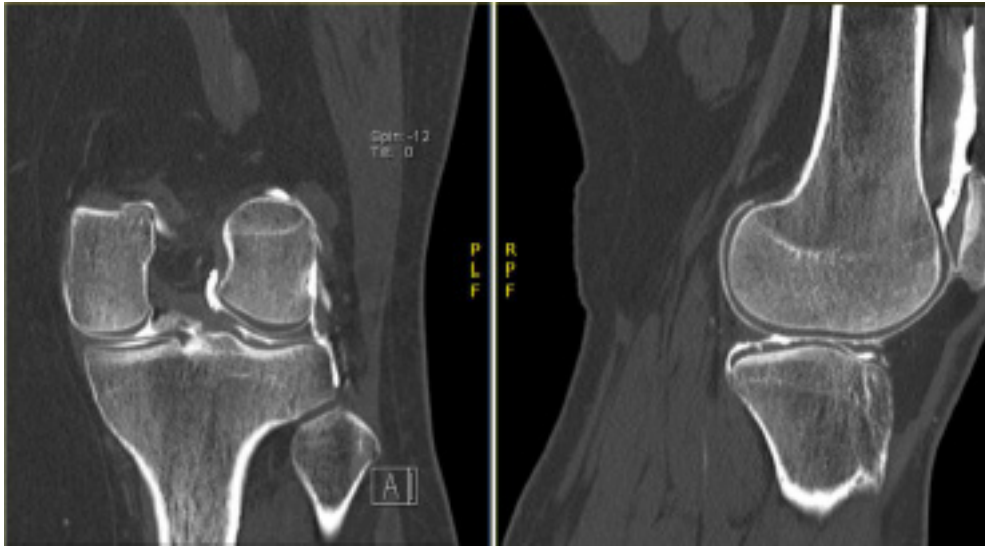
The patient is a female, early 40. She presented with left knee pain and mechanical symptoms especially under weight-bearing, which started 8 months ago. Co-morbidities included obesity ($30 > \text{BMI} > 35$) and BPCO. No history of previous trauma or past surgery on the affected limb are known.

Clinical examination

Gait appeared normal. A bilateral genu valgum was observed. It was more pronounced in the left knee compared to the contralateral side. Both knees showed no effusion, were stable and had free range of motion (0° - 0° - 120°). Pain was reported on palpation of the lateral femoro-tibial joint space. No neurological or vascular abnormality of the lower limbs was detected.

Radiological analysis

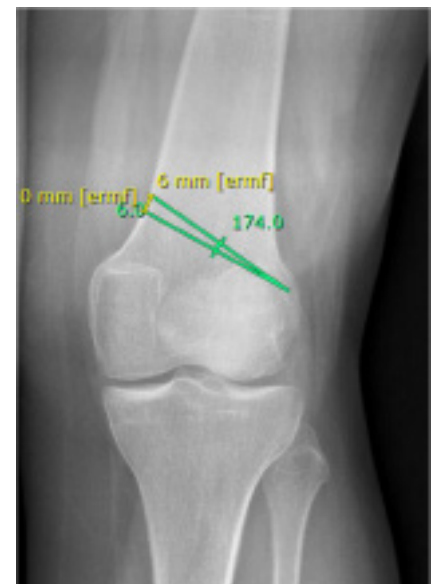To evaluate the knee a long leg standing X-ray and an ArthroCT scan with coronal, sagittal and axial views were prescribed. The ArthroCT scan showed an isolated grade III osteoarthritis in the lateral femorotibial joint. The long leg standing X-rays confirmed the presence of a bilateral genu valgum and were used for subsequent surgical planning.

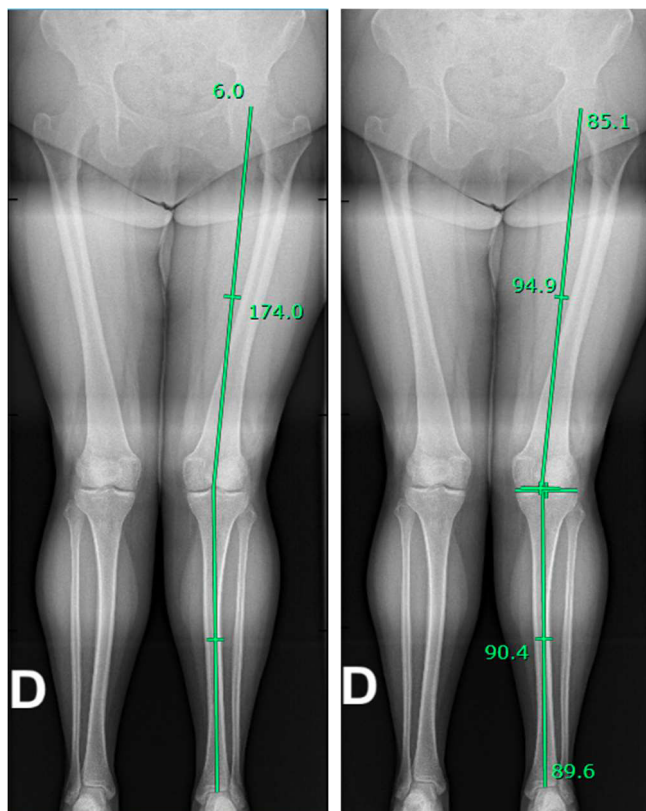


SURGERY

Considering the young age of the patient and the extra-articular deformity, unicompartmental and total knee replacement were excluded and it was decided to focus on joint preserving procedures. Given the presence of a valgus alignment coupled with the presence of isolated lateral compartment knee osteoarthritis a realignment procedure was chosen.

To plan the surgical treatment, long leg standing X-rays were used. Upon calculation the overall left limb alignment showed a valgus of 6° with a lateral distal femoral angle (LDFA) of 85.1° and medial proximal tibial angle (MTPA) of 90.4° . Considering the neutral tibial axis, a femoral axis correction with a medial closing distal femoral osteotomy (DFO) was planned to reach neutral knee alignment. A correction of 6° was chosen, corresponding to a 6 mm resection.





The procedure was performed in dorsal decubitus under general anesthesia without tourniquet, including the hip into the sterile surgical field to allow appraisal of the full limb alignment during the whole procedure.

A 15 cm skin incision was started 2 centimeters distal and anterior to the medial epicondyle and extended proximally. The fascia of the vastus medialis was dissected and retracted laterally and anteriorly to expose the femoral shaft.

After that, 2 pins were placed under fluoroscopy to mark the osteotomy line. A blunt retractor was positioned posterior to the shaft to protect the neurovascular structures during the osteotomy cut. A biplanar osteotomy was performed with an oscillating saw cutting up to 1 centimeter from the lateral cortex. A second cut was performed 6 millimeters proximally and the resulting bone slice of 6 millimeters was removed to achieve the desired correction. The medial wedge was progressively closed and a Newclip medial closing DFO plate was placed.

The plate was fixed with 4 distal and 4 proximal self-locking screws using Newclip's specific instrumentation while keeping the leg in maximal extension to favor compression of the osteotomy site. Final verification of the correction under fluoroscopy showed the Mikulicz's line passing at the medial part of the medial tibial spine. Postoperative X-rays were taken on the first day before patient's discharge home.

Post-operative follow-up :

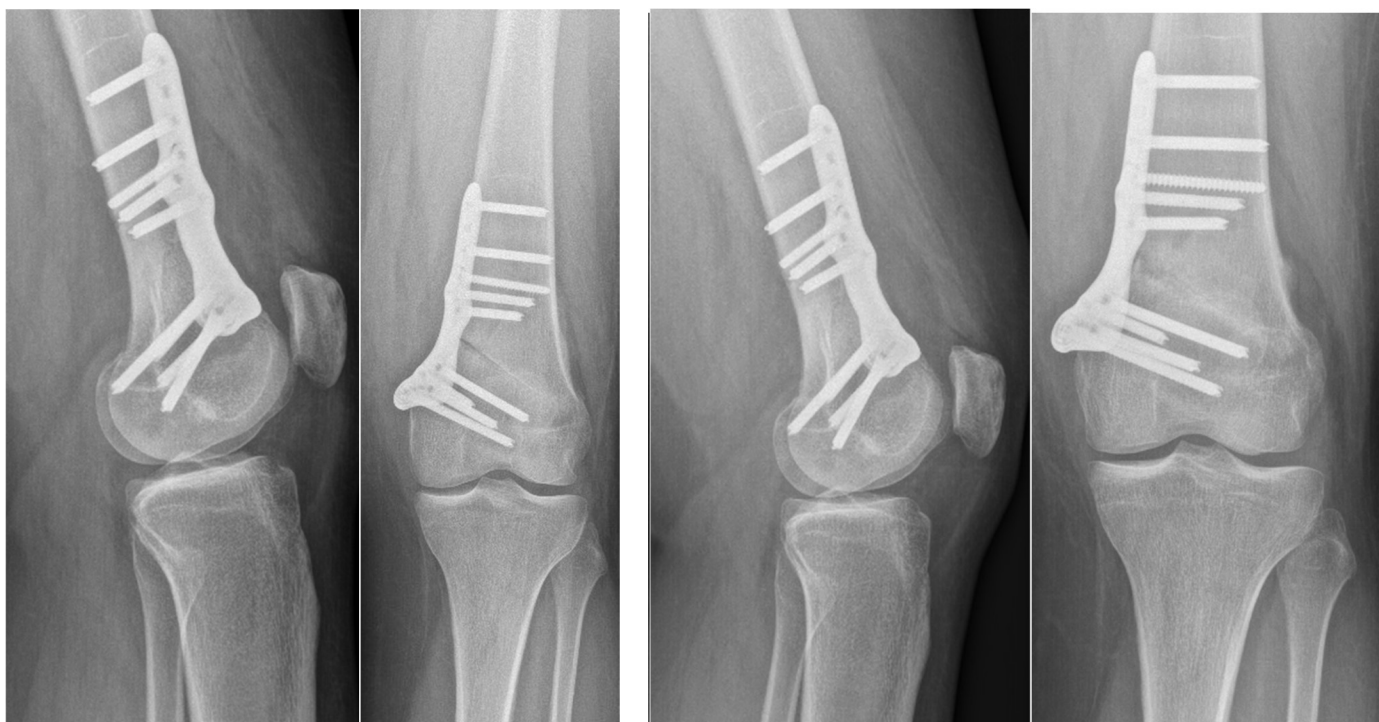Fifteen kilograms partial weightbearing was allowed for the first 6 postoperative weeks. Free knee range of motion was permitted starting from the first postoperative day. Regular passive mobilization exercises and physiotherapy were prescribed to try to avoid postoperative stiffness.

Stitches were removed after 2 weeks.

Full weightbearing was started after 6 weeks.

Imaging follow-up was carried out performing postoperative X-rays at: 3 weeks, 6 weeks and 3 months.

At 3 months follow-up, the patient had a free range of motion without pain during full weight bearing.



Postoperative X-rays : day 1 after surgery

Postoperative X-rays : 3 months after surgery

Physician conclusion

Newclip Technics with their ACTIVMOTION S line offers plates and ancillaries with a design ideal to respect the anatomy of the distal femur and preserve the integrity of the neurovascular structures, while not compromising the stability of the bone corrections obtained. The instrumentation is elegant and intuitive and allows precise calibration of the osteotomy cuts, as well as optimal compression and stability in medial closing DFOs.

NEWCLIP TECHNICS

45 rue des Garottières
44115 Haute Goulaine, France
+33 (0)2 28 21 37 12
orders@newcliptechnics.com

www.newcliptechnics.com

NEWCLIP TECHNICS GERMANY

Newclip GmbH
Pröllstraße 11
D-86157 Augsburg, Germany

+49 (0)821 650 749 40
info@newclipgmbh.com

www.newclipgmbh.de

NEWCLIP TECHNICS USA

Newclip USA
340 Tesconi Circle Suite A
Santa Rosa CA 95403, USA

+1 707 230 5078
customerservice@newclipusa.com

www.newclipusa.com

NEWCLIP TECHNICS AUSTRALIA

Newclip Australia
3B/11 Donkin Street
West End 4101, Australia

+61 (0)2 81 886 110
solutions@newclipaustralia.com

www.newcliptechnics.com

NEWCLIP TECHNICS JAPAN

Newclip Technics Japan K.K.
KKK Bldg. 502, 3-18-1 Asakusabashi
Taito-Ku, Tokyo, 111-0053, Japan

+81 (0)3 58 25 49 81
Fax: +81 (0)3 58 25 49 86

www.newcliptechnics.com

NEWCLIP TECHNICS IBERIA

Newclip Iberia
Calle Frederic Mompou, 4b
Sant Just Desvern, 08960 Barcelona, Spain

+34 938 299 526
contact@newclipiberia.com

www.newcliptechnics.com

NEWCLIP TECHNICS BELGIUM

Newclip Belgium
Derbystraat 43
1059 Sint-Denijs-Westrem

09 231 13 31
contact@newclipbelgium.com

www.newcliptechnics.com